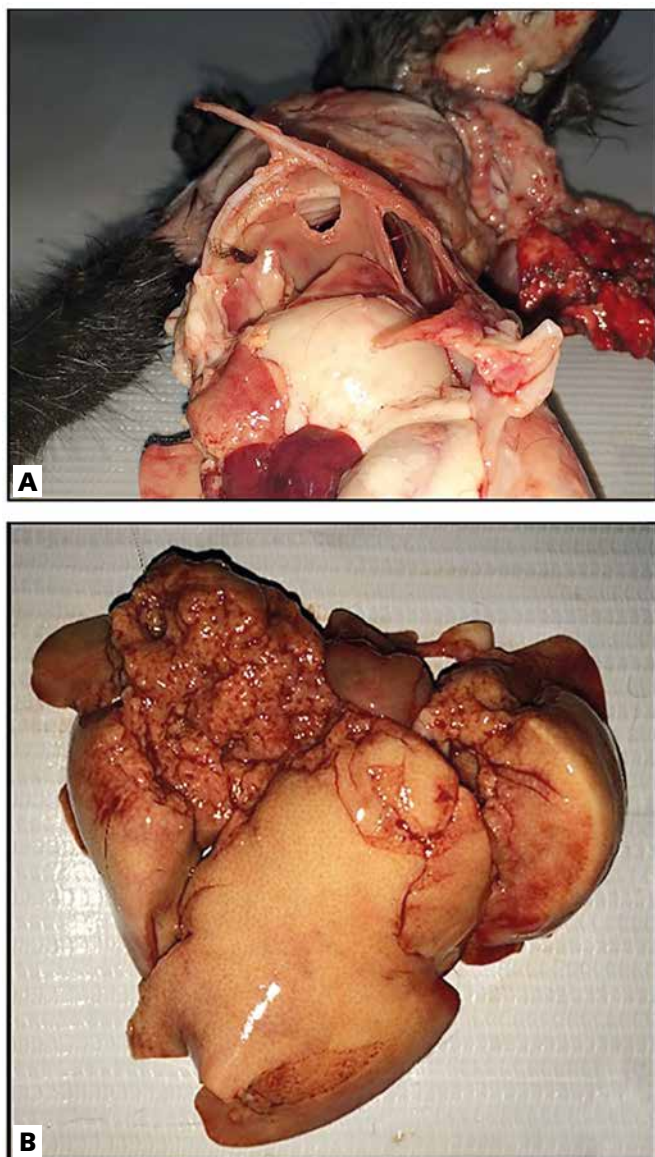

**Figure 2** - (A) Rib fracture and traumatic diaphragm herniation from inside view. (B) Liver traumatic laceration in evidence.

Source: Laboratório de Patologia e Medicina Veterinária Legal da Faculdade de Veterinária da Universidade Estadual do Ceará.

**Conclusion:** The conclusion, was that hit and runs, like in human medicine are common cause of trauma and deaths in veterinary medicine. It is important to identify the lesions and correlate than to the cause of death in order to help gather data about animal abuse. This kind of data is important because it helps to bring attention to this kind of crimes that are increasing and are still underestimated in nowadays society. For this matter, it is important to have

a well prepared team to perform this kind of procedure and help the justice with a fine and well-structured report that can be used later as a court material.

### References

ARMED FORCES INSTITUTE OF PATHOLOGY. **Technical Bulletin Med. n° 283**: veterinary necropsy protocol for military working dogs and pathology specimen submission guidelines. Washington, D.C.: Department of the Army, 2001.

BROWNLIE, H. W. B.; MUNRO, R. The veterinary forensic necropsy: a review of procedures and protocols. **Veterinary Pathology**, Thousand Oaks, v. 53, n. 5, p. 919-928, 2016.

DODD, M. J. Traffic deaths. In: SIEGEL, J. A.; SAUKKO, P. J.; KNUPFER, G. C. (Eds.). **Encyclopedia of Forensic Sciences**. London: Academic Press, 2000. v. 1, p. 353-358.

GOWER, S. B.; WEISSE, C. W; BROWN, D. C. Major abdominal evisceration injuries in dogs and cats: 12 cases (1998-2008). **Journal of the American Veterinary Medical Association**, Ithaca, v. 234. p. 1566-1572, 2009.

LOCKWOOD, R.; ARKOW, P. Animal abuse and interpersonal violence: the cruelty connection and its implications for veterinary pathology. **Veterinary Pathology**, Thousand Oaks, v. 53, n. 5, p. 910-918, 2016.

### **PATHOLOGIC FINDINGS IN 48 DOGS EXPOSED TO NONACCIDENTAL TRAUMA (PHYSICAL ABUSE) IN THE CENTRAL REGION OF RIO GRANDE DO SUL, BRAZIL**

RAMOS, C. P.<sup>1</sup>; FIGHERA, R. A.<sup>2</sup>; FLORES, M. M.<sup>2</sup>

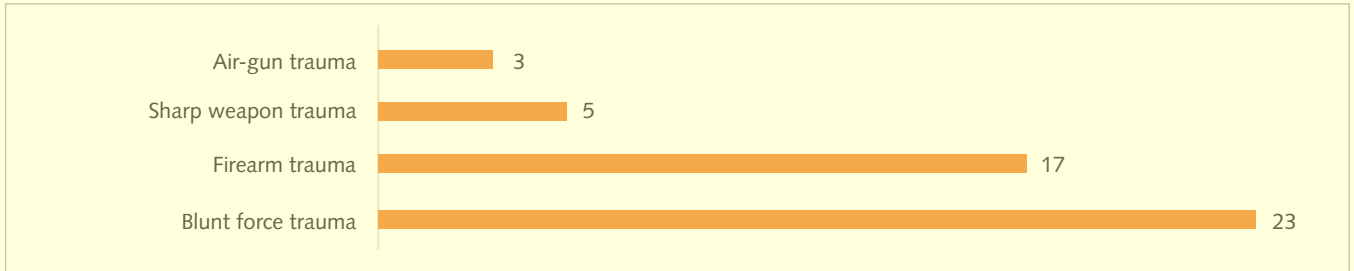
<sup>1</sup> Acadêmica do curso de Medicina Veterinária, Bolsista do Laboratório de Patologia Veterinária da Universidade Federal de Santa Maria (UFSM). E-mail: crprader@gmail.com.

<sup>2</sup> Médico-veterinário, professor adjunto do Laboratório de Patologia Veterinária da UFSM.

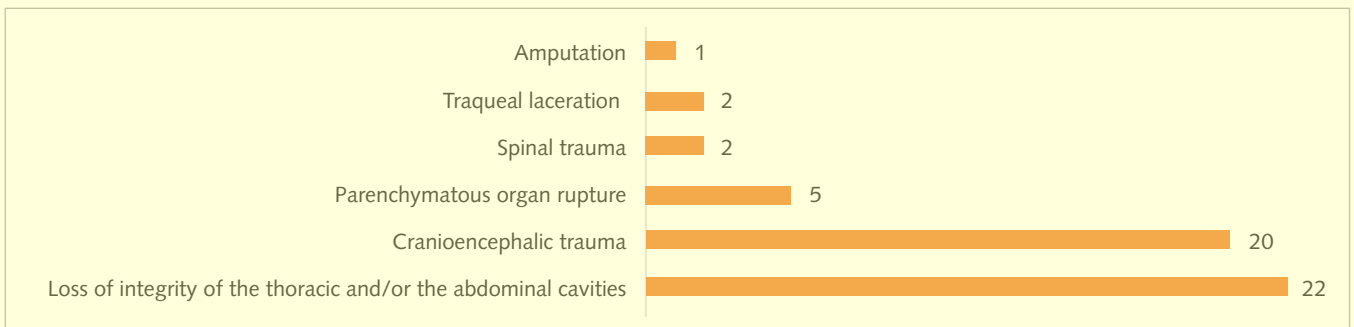
**Introduction:** Over the last years, the human society has been demonstrating an increasing interest in the prosecution of crimes against animals (LOCKWOOD, 2006). As a consequence of the growing connection and dependence between humans and animals, the laws regarding animal abuse have become more specific and rigid (FARACO, 2008). Based on this fact, the number of studies concerning post mortem

findings in cases of animal abuse have increased over the years. The aim of this study was to analyze the post mortem findings in all canine necropsy cases confirmed as “nonaccidental trauma” at the Laboratório de Patologia Veterinária from the Universidade Federal de Santa Maria (LPV-UFSM) from 1964 to 2016. **Method:** The necropsy files of all dogs submitted to necropsy at the LPV-UFSM (1964-2016) were searched, and only those cases where trauma was readily confirmed as “nonaccidental” were included. Information

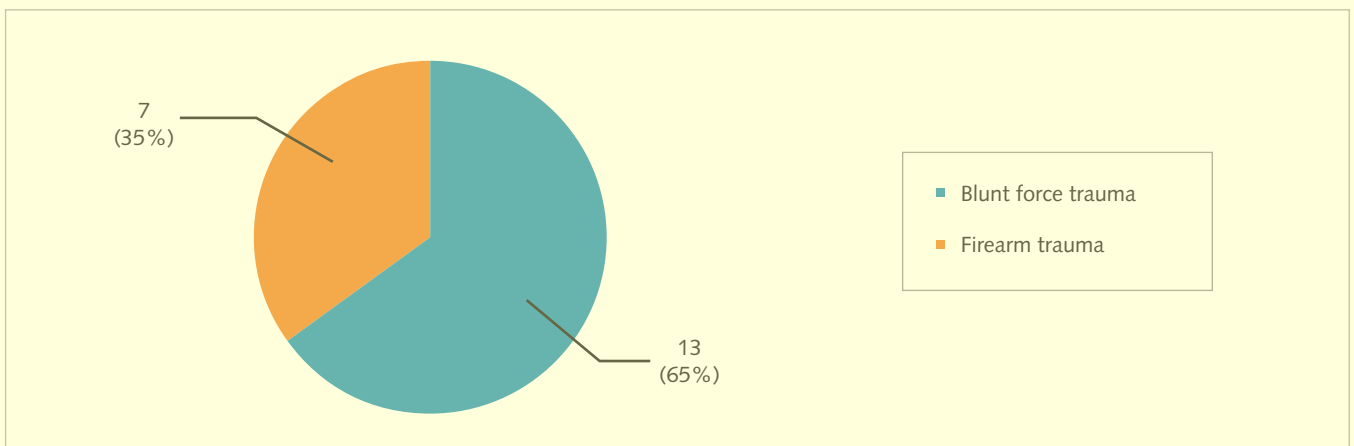
regarding gender, age and necropsy findings were collected. **Results:** A total of 48 dogs were included. Of the dogs with complete information regarding gender, 27 were males and 15 were females. The dogs with complete information regarding to age were distributed as follows: 28 (1 to 9 years-old), 11 (0 to 11 months-old) and three (10 years or more). All cases were divided into four categories according to the source of physical trauma (Figure 1). All traumatic injuries leading to or contributing with death are demonstrated in Figure 2.



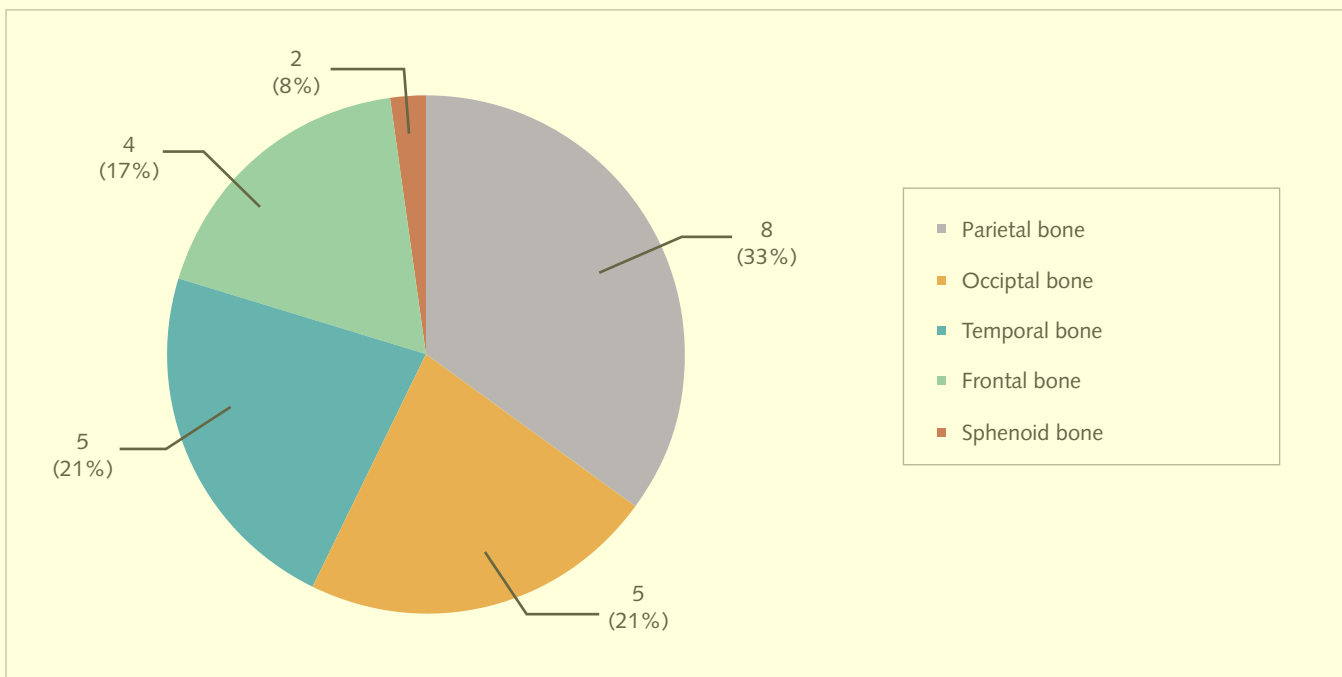
**Figure 1** - Source of nonaccidental trauma (physical abuse) in dogs necropsied at LPV-UFSM (1964-2016). Source: Rafael Almeida Figuera.



**Figure 2** - Injuries in dogs exposed to nonaccidental trauma (physical abuse) and necropsied at LPV-UFSM (1964-2016). Source: Rafael Almeida Figuera.

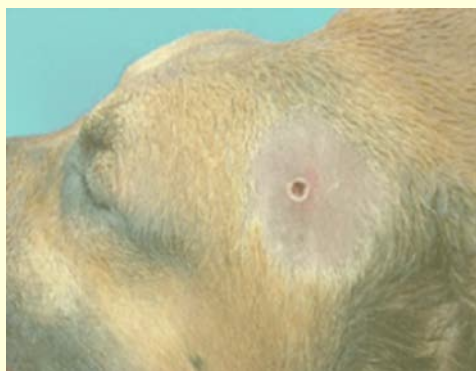

**Figure 3** - Source of aggression leading to cranioencephalic trauma in 20 dogs necropsied at LPV-UFSM (1964-2016). Source: Rafael Almeida Figuera.

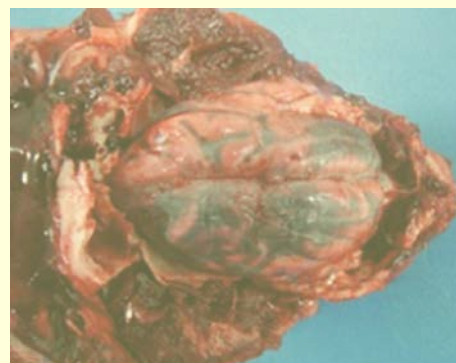


**Figure 4** - Sites of 24 fractures observed in 16 dogs submitted to nonaccidental cranioencephalic trauma and necropsied at LPV-UFSM (1964-2016).  
Source: Rafael Almeida Figuera.

The thoracic cavity (12) was more frequently affected by perforation or rupture (loss of integrity) when compared to the abdominal cavity (10). Of all cases that involved loss of integrity of any cavity, the type of aggression included: 14 firearm traumas, five sharp weapon traumas and three air-gun traumas. Of the 20 cases of cranioencephalic trauma (Figure 3), 16 involved cranial fractures (Figure 4). Two lesions caused by firearm and blunt force trauma are shown in Figures 5 and 6, respectively.



**Figure 5** - Head, dog. Cutaneous wound caused by a firearm.  
Source: Rafael Almeida Figuera.



**Figure 6** - Brain, dog. Subdural hematoma caused by blunt force trauma.  
Source: Rafael Almeida Figuera.

**Discussion:** Based on this retrospective study it was determined that “blunt force trauma” was the most frequent type of aggression in dogs submitted to necropsy in the Central Region of Rio Grande do Sul, Brazil. The most common causes of death involved rupture of the thoracic and/or abdominal cavities and cranioencephalic trauma. Cases of animal abuse are certainly underrepresented in the necropsy floor for a number of different reasons. For instance, many aggressions remain undiscovered because no witness was present at the

time of the abuse, and therefore, the animal is not taken for post mortem investigation. Another reason is that wounds caused by sharp weapons, firearms or air-guns may not be readily visible at the time of necropsy due to the animal's hair coat (SIQUEIRA *et al.*, 2016). Additionally, it is particularly difficult to determine, in some circumstances, if the trauma was accidental or not. Thus, the clinical history is particularly important in necropsy cases where animal abuse is suspected.

**Conclusion:** Even with the existence of stronger laws, the practice of animal abuse is not properly punished in Brazil (MERCK, 2008; MUNRO; MUNRO, 2008). The publication of more studies concerning this subject in the country may help propagating the importance and seriousness of animal aggression nowadays, thus, leading to more dramatic changes in the way that humans interact with animals.

### References

- FARACO, C. B. Interação humano-animal. *Ciência Veterinária nos Trópicos*, Recife, v. 11, p. 31-35, 2008. Suplemento 1.
- LOCKWOOD, R. **Animal cruelty prosecution:** opportunities for early response to crime and interpersonal violence. Alexandria: American Prosecutors Research Institute, 2006.
- MERCK, M. D. **Veterinary forensics:** animal cruelty investigations. 2. ed. Iowa: Wiley-Blackwell, 2008.
- MUNRO, H. M. C; MUNRO, R. **Animal abuse and unlawful killing:** forensic veterinary pathology. Londres: Elsevier Health Sciences, 2008.
- SIQUEIRA, A. *et al.* Forensic veterinary pathology: sharp injuries to animals. *Veterinary Pathology*, Thousand Oaks, v. 53, n. 5, p. 979-987, 2016.

### POST-TRAUMATIC HYDROCEPHALUS IN A DOG

LOPES, C. E. B.<sup>1</sup>; VIANA, D. A.<sup>2</sup>; MATOS, M. G.<sup>1</sup>; RODRIGUES, F. R. N.<sup>1</sup>; PIMENTEL, S. P.<sup>1</sup>

<sup>1</sup> Estudante de graduação em Medicina Veterinária da Universidade Estadual do Ceará (Uece). E-mail: 1993carlos.eduardo@gmail.com.

<sup>2</sup> Professor Doutor de Patologia Veterinária da Faculdade de Veterinária da Uece e diretor-técnico-científico do Laboratório de Anatomia Patológica e Patologia Clínica S/S LTDA (Pathovet) (<http://www.pathovet.com.br>).

**Introduction:** Hydrocephalus is a condition when an exacerbated amount of cerebral spinal fluid (CSF),

occurring due to an abnormally high production, poor drainage or obstructions in the normal flow, is accumulated in the head, generally occasioning an initial dilation of the lateral ventricles, and culminating in many neurological signs, depending on its cause and severity. Additionally, it could be also associated with head traumas, and in these cases, the forensic necropsy is a necessary tool to elucidate all circumstances involved, establishing a perfect correlation between legal and medical aspects especially when there is doubt of a possible crime. The present paper is a case report of a traumatic injury leading to a hydrocephalus condition.

**Methods:** Except the physical exam and the X-Ray, performed in a local Veterinarian Emergency establishment, all procedures were conducted in the Laboratório Pathovet<sup>®</sup>, in Fortaleza, Ceará, using the modified technique of a veterinary necropsy protocol from the Armed Forces Institute of Pathology (Afip) (ARMED FORCES INSTITUTE OF PATHOLOGY, 2001) for necroscopic exam guidelines. **Results:** In September, 12<sup>th</sup> of 2012, a 2-month-old female Yorkshire Terrier, previously acquired in a local Pet Store, was presented to the emergency service demonstrating general pain with constant vocalization, apathy, abdominal sensitivity, pale mucous membranes and dehydration. During clinical examination, a small depression was noted in the head of the puppy and the X-Ray showed cortical discontinuity in frontal and dorsal regions of skull cap leading to a previous diagnosis of hydrocephalus. The guardian insisted that it was a congenital condition brought with the pet at the moment of the deal and not acquired within his house. Despite the efforts, the animal did not respond to treatment with a notorious worsening of symptoms. Thus, with no hope of improvement, the guardian requested its euthanasia and demanded of the owner of the Pet Store a new puppy. Therefore, it was submitted to euthanasia and stored in freezer. Since a dispute was settled around the death of the animal, a forensic necropsy was performed to clarify the actual circumstances of the case. Although the necropsy revealed a good external condition, it was perceived a slight depression in the cephalic region. The main finding in internal exam was Cranial-Cephalic Traumatism with irregular fracture of occipital bone causing a severe subcutaneous and cerebral hemorrhage, as well as an acquired hydrocephalus (Figure 1).