

time of the abuse, and therefore, the animal is not taken for post mortem investigation. Another reason is that wounds caused by sharp weapons, firearms or air-guns may not be readily visible at the time of necropsy due to the animal's hair coat (SIQUEIRA *et al.*, 2016). Additionally, it is particularly difficult to determine, in some circumstances, if the trauma was accidental or not. Thus, the clinical history is particularly important in necropsy cases where animal abuse is suspected.

**Conclusion:** Even with the existence of stronger laws, the practice of animal abuse is not properly punished in Brazil (MERCK, 2008; MUNRO; MUNRO, 2008). The publication of more studies concerning this subject in the country may help propagating the importance and seriousness of animal aggression nowadays, thus, leading to more dramatic changes in the way that humans interact with animals.

## References

FARACO, C. B. Interação humano-animal. **Ciência Veterinária nos Trópicos**, Recife, v. 11, p. 31-35, 2008. Suplemento 1.

LOCKWOOD, R. **Animal cruelty prosecution: opportunities for early response to crime and interpersonal violence**. Alexandria: American Prosecutors Research Institute, 2006.

MERCK, M. D. **Veterinary forensics: animal cruelty investigations**. 2. ed. Iowa: Wiley-Blackwell, 2008.

MUNRO, H. M. C; MUNRO, R. **Animal abuse and unlawful killing: forensic veterinary pathology**. Londres: Elsevier Health Sciences, 2008.

SIQUEIRA, A. *et al.* Forensic veterinary pathology: sharp injuries to animals. **Veterinary Pathology**, Thousand Oaks, v. 53, n. 5, p. 979-987, 2016.

## POST-TRAUMATIC HYDROCEPHALUS IN A DOG

LOPES, C. E. B.<sup>1</sup>; VIANA, D. A.<sup>2</sup>; MATOS, M. G.<sup>1</sup>; RODRIGUES, F. R. N.<sup>1</sup>; PIMENTEL, S. P.<sup>1</sup>

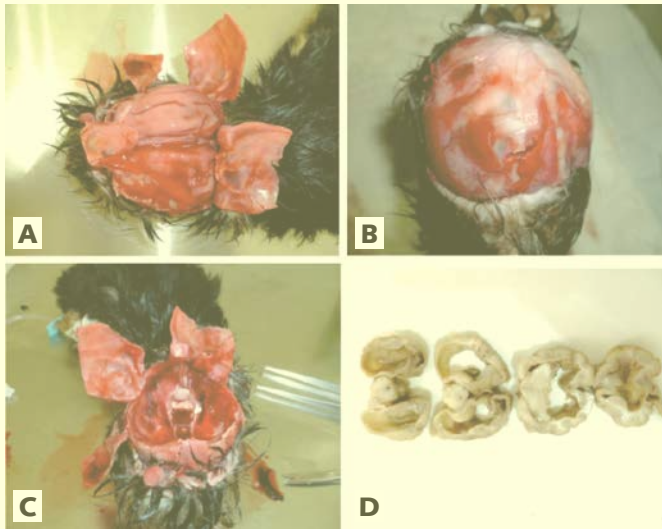
<sup>1</sup> Estudante de graduação em Medicina Veterinária da Universidade Estadual do Ceará (Uece). E-mail: 1993carlos.eduardo@gmail.com.

<sup>2</sup> Professor Doutor de Patologia Veterinária da Faculdade de Veterinária da Uece e diretor-técnico-científico do Laboratório de Anatomia Patológica e Patologia Clínica S/S LTDA (Pathovet) (<http://www.pathovet.com.br>).

**Introduction:** Hydrocephalus is a condition when an exacerbated amount of cerebral spinal fluid (CSF),

occurring due to an abnormally high production, poor drainage or obstructions in the normal flow, is accumulated in the head, generally occasioning an initial dilation of the lateral ventricles, and culminating in many neurological signs, depending on its cause and severity. Additionally, it could be also associated with head traumas, and in these cases, the forensic necropsy is a necessary tool to elucidate all circumstances involved, establishing a perfect correlation between legal and medical aspects especially when there is doubt of a possible crime. The present paper is a case report of a traumatic injury leading to a hydrocephalus condition.

**Methods:** Except the physical exam and the X-Ray, performed in a local Veterinarian Emergency establishment, all procedures were conducted in the Laboratório Pathovet<sup>®</sup>, in Fortaleza, Ceará, using the modified technique of a veterinary necropsy protocol from the Armed Forces Institute of Pathology (Afip) (ARMED FORCES INSTITUTE OF PATHOLOGY, 2001) for necroscopic exam guidelines. **Results:** In September, 12<sup>th</sup> of 2012, a 2-month-old female Yorkshire Terrier, previously acquired in a local Pet Store, was presented to the emergency service demonstrating general pain with constant vocalization, apathy, abdominal sensitivity, pale mucous membranes and dehydration. During clinical examination, a small depression was noted in the head of the puppy and the X-Ray showed cortical discontinuity in frontal and dorsal regions of skull cap leading to a previous diagnosis of hydrocephalus. The guardian insisted that it was a congenital condition brought with the pet at the moment of the deal and not acquired within his house. Despite the efforts, the animal did not respond to treatment with a notorious worsening of symptoms. Thus, with no hope of improvement, the guardian requested its euthanasia and demanded of the owner of the Pet Store a new puppy. Therefore, it was submitted to euthanasia and stored in freezer. Since a dispute was settled around the death of the animal, a forensic necropsy was performed to clarify the actual circumstances of the case. Although the necropsy revealed a good external condition, it was perceived a slight depression in the cephalic region. The main finding in internal exam was Cranial-Cephalic Traumatism with irregular fracture of occipital bone causing a severe subcutaneous and cerebral hemorrhage, as well as an acquired hydrocephalus (Figure 1).



**Figure 1** - Skull and brain evaluation. (A) Cranial lesions. (B) Hemorrhage and blood clots on brain surface. (C) Cranial floor with CSF-blood mixed solution. (D) Coronal segments of encephalon showing intense hydrocephalus. Source: Universidade Estadual do Ceará.

**Discussion:** When speaking about young dogs and cats, it is known that the both species share some particularities by not staying out of trouble. Inevitably, as a gradual and normal discovering process, the young animals are more susceptible to hazardous situations, considering that it is common to this early phase the continuous exploration and jokes, allowing the occurrence of accidental falls, kicks, among other traumas, that culminate sometimes with serious head traumas or even death. Indeed, the age, port and weight seem to perform an important role in the frequency and severity of traumatic cases. In the present case, the owners' dilemma was to consider the possibility of trauma in their possession. We consider that the accident could have occurred in some moment of distraction or negligence, in which the animal could have possibly fallen on a solid surface. To sustain this point of view, it was verified that the trauma was *peri mortem*, occurring in a way directly related to death, by presenting hemorrhage and "green-bone" fractures of the skull cap (Figure 1A), signaling a blunt trauma in an alive bone, generating sharp edges. Equally, the bone breakage of one or more sutures occur in diastatic fractures, by applying a powerful force in the bone surface, mostly common in puppies, because the sutures are still not fully consolidated. Moreover, the physical meningeal damage and blood clots are known to cause CSF obstruction, with a variety of clinical signs depending on the affected structures. Generally, the first

portions to be affected by the blockage of the CSF flow are the lateral ventricles since it is a zone with great volume of fluid secretion. Thus, the Figure 1D expresses the devastating consequences of this enhancement of pressure, committing more than a half of the normal cerebral tissue and being responsible for the loss of a considerable amount of brain matter. Yet, although hydrocephalus seems to be very advanced for such a recent trauma, there were no evidence to support a congenital hydrocephalus because no accurate exams were made since the animal was born, especially because it presented no clinical signs on the moment it was acquired. Moreover, the animal was exposed in the pet store by being apparently health and responsive, together with a normal weight and body condition score for its age, contradictorily to what is explained by Przyborowska *et al.* (2013) for suspicions of congenital hydrocephalus. **Conclusion:** The hydrocephalus condition, as well as the previous symptoms, was attributed to a recent cranial trauma, leading to a fatal chain effect by the occurrence of hemorrhage and CSF flow obstruction.

### References

ARMED FORCES INSTITUTE OF PATHOLOGY. **Technical Bulletin Med. n° 283:** veterinary necropsy protocol for military working dogs and pathology specimen submission guidelines. Washington, D.C.: Department of the Army, 2001. PRZYBOROWSKA, P. *et al.* Hydrocephalus in dogs: a review. **Veterinarni Medicina**, Praga, v. 58, n. 2, p. 73-80, 2013.

### UNLEASHING THE DOG: CANINE ATTACK OF 17 VICTIMS WITH THE SAME MODUS OPERANDI

LOPES, C. E. B.<sup>1</sup>; VIANA, D. A.<sup>2</sup>; MATOS, M. G.<sup>1</sup>; RODRIGUES, F. R. N.<sup>1</sup>; PIMENTEL, S. P.<sup>1</sup>; PESSOA, A. W. P.<sup>3</sup>

<sup>1</sup> Estudante de graduação em Medicina Veterinária da Universidade Estadual do Ceará (Uece). E-mail: 1993carlos.eduardo@gmail.com.

<sup>2</sup> Professor Doutor de Patologia Veterinária da Faculdade de Veterinária da Uece e diretor-técnico-científico do Laboratório de Anatomia Patológica e Patologia Clínica S/S LTDA (Pathovet) (<http://www.pathovet.com.br>).

<sup>3</sup> Professora Doutora de Patologia Veterinária da Faculdade de Veterinária da Uece.

**Introduction:** Dogs are usually friendly companions, being variably used by men for hunting, protecting,