

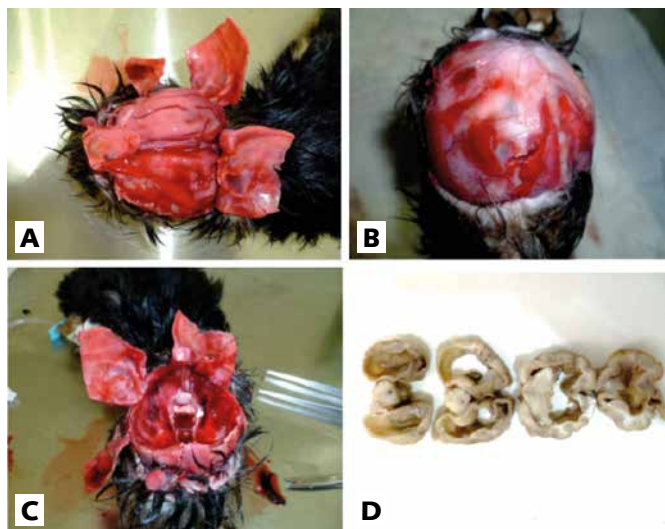Figure 1 - Skull and brain evaluation. (A) Cranial lesions. (B) Hemorrhage and blood clots on brain surface. (C) Cranial floor with CSF-blood mixed solution. (D) Coronal segments of encephalon showing intense hydrocephalus. Source: Universidade Estadual do Ceará.

Discussion: When speaking about young dogs and cats, it is known that the both species share some particularities by not staying out of trouble. Inevitably, as a gradual and normal discovering process, the young animals are more susceptible to hazardous situations, considering that it is common to this early phase the continuous exploration and jokes, allowing the occurrence of accidental falls, kicks, among other traumas, that culminate sometimes with serious head traumas or even death. Indeed, the age, port and weight seem to perform an important role in the frequency and severity of traumatic cases. In the present case, the owners' dilemma was to consider the possibility of trauma in their possession. We consider that the accident could have occurred in some moment of distraction or negligence, in which the animal could have possibly fallen on a solid surface. To sustain this point of view, it was verified that the trauma was *peri mortem*, occurring in a way directly related to death, by presenting hemorrhage and "green-bone" fractures of the skull cap (Figure 1A), signaling a blunt trauma in an alive bone, generating sharp edges. Equally, the bone breakage of one or more sutures occur in diastatic fractures, by applying a powerful force in the bone surface, mostly common in puppies, because the sutures are still not fully consolidated. Moreover, the physical meningeal damage and blood clots are known to cause CSF obstruction, with a variety of clinical signs depending on the affected structures. Generally, the first

portions to be affected by the blockage of the CSF flow are the lateral ventricles since it is a zone with great volume of fluid secretion. Thus, the Figure 1D expresses the devastating consequences of this enhancement of pressure, committing more than a half of the normal cerebral tissue and being responsible for the loss of a considerable amount of brain matter. Yet, although hydrocephalus seems to be very advanced for such a recent trauma, there were no evidence to support a congenital hydrocephalus because no accurate exams were made since the animal was born, especially because it presented no clinical signs on the moment it was acquired. Moreover, the animal was exposed in the pet store by being apparently health and responsive, together with a normal weight and body condition score for its age, contradictorily to what is explained by Przyborowska *et al.* (2013) for suspicions of congenital hydrocephalus. **Conclusion:** The hydrocephalus condition, as well as the previous symptoms, was attributed to a recent cranial trauma, leading to a fatal chain effect by the occurrence of hemorrhage and CSF flow obstruction.

References

ARMED FORCES INSTITUTE OF PATHOLOGY. **Technical Bulletin Med. n° 283:** veterinary necropsy protocol for military working dogs and pathology specimen submission guidelines. Washington, D.C.: Department of the Army, 2001.

PRZYBOROWSKA, P. *et al.* Hydrocephalus in dogs: a review. **Veterinarni Medicina**, Praga, v. 58, n. 2, p. 73-80, 2013.

UNLEASHING THE DOG: CANINE ATTACK OF 17 VICTIMS WITH THE SAME MODUS OPERANDI

LOPES, C. E. B.¹; VIANA, D. A.²; MATOS, M. G.¹; RODRIGUES, F. R. N.¹; PIMENTEL, S. P.¹; PESSOA, A. W. P.³

¹ Estudante de graduação em Medicina Veterinária da Universidade Estadual do Ceará (Uece). E-mail: 1993carlos.eduardo@gmail.com.

² Professor Doutor de Patologia Veterinária da Faculdade de Veterinária da Uece e diretor-técnico-científico do Laboratório de Anatomia Patológica e Patologia Clínica S/S LTDA (Pathovet) (<http://www.pathovet.com.br>).

³ Professora Doutora de Patologia Veterinária da Faculdade de Veterinária da Uece.

Introduction: Dogs are usually friendly companions, being variably used by men for hunting, protecting,

grazing, guiding or rescuing purposes, besides the world-wide known companion use as a pet. The man's best friend behaves according to stimuli imposed by its tutor, being able to become aggressive and even attack when ordered. Yet, though behavioral deviances can occur, representing a rare portion of accidents with humans or other animals, it may be partially our fault in misunderstanding the given signals or, even misleading the dog to a stressful situation. While some cats and dogs *get along* well, others may not. In some cases, a dog might chase and attack a cat. Signs of aggression from a dog toward a cat represents an aggressive behavior sometimes induced by its tutor. The diagnosis of injuries inflicted by dogs can often be established based on typical tooth marks at the edges of the wounds. Three categories of wounds may be identified: non-fatal dog bite wounds; severe dog bites that directly, or indirectly, lead to the victim's death; and post mortem lacerations of the victim's body. The difference between an *ante-mortem* and *post-mortem* injury is very often possible only during necropsy, when it is investigated the trajectory of the attack in the vital organs and performed the histopathologic exams, which enable the differentiation between a true hemorrhage in an alive tissue or not. Here it is described the attack of 17 stray cats killed under the same circumstances: reiterated type of lesion and a common unknown dog. **Methods:** All procedures were performed by the service of Pathology and Legal Medicine of the Ceará State University, using the modified technique of a veterinary necropsy protocol from the Armed Forces Institute of Pathology – Afip (ARMED FORCES INSTITUTE OF PATHOLOGY, 2001) for necroscopic exam guidelines, which are mainly based on adaptations for the veterinary reality of the well-known techniques of Ghon and Virchow, routinely used in human medicine. The investigation of the crime scene, followed established recommendations about carcass evaluation and environmental analysis, which mostly consists of photographing the scenario with and without the corpse, together with the surroundings, describing the situation and condensing clues, sometimes being necessary to collect biological or environmental materials, in the way to evidence any hidden information directly or indirectly relevant to the case. **Results:** In total, 17 stray cats of various ages were randomly found in areas of the Campus of Itaperi from Ceará State University (Figure 1) in a period of 17 consecutive weeks. The number of deaths presented an

approximated rhythm of 1 animal/week, all in a same area and day of week (Monday).




Figure 1 - Field findings. (A) and (B) Crime scenes with blood traces (arrows) and revolved sand (right).

Source: Universidade Estadual do Ceará.

During the crime scene investigation, it was found revolved sand and, sometimes, irregular blood marks beside the dead body (Figure 1). In a previous external exam, it was presumed a mean time of death of eight to 12 hours before. In necropsy, most animals were young, and all presented an equal pattern of external lesions: blunt-stabbing lesions mostly localized in thorax and nape, always in pairs, by showing symmetrical wounds (3,0 x 2,0 centimeters) and characterizing extensive tissue destruction and hemorrhage. It is also highlighted that for the adult cats, additional perforations in thorax and abdomen were additionally common. (Figure 2). The animals exhibited a slight or non-rigor mortis condition.

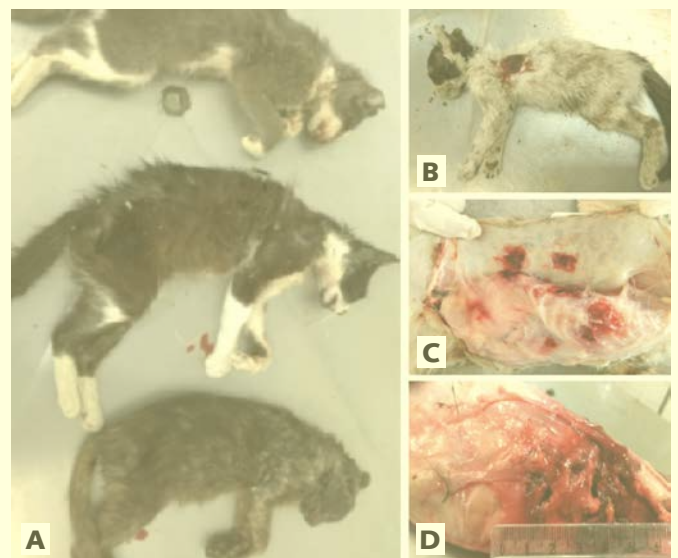


Figure 2 - Characterization of wounds. (A) Animals found in Campus. (B) Sites of perforation and external aspect. (C) Multiple blunt-stabbing type lesions. (D) Dimension and extension of injury in vital organs.

Source: Universidade Estadual do Ceará.

Discussion: Although crime scene investigation was not enough to estimate if the animals were killed in the location or if they conscientiously dragged themselves until there, the suspicion was that the animals died in those areas, and not randomly discarded, by presenting blood traces all around the place (Figures 1.A and B). Considering the lesions pattern, a possible dog attack could be the deaths cause, and maybe by a same dog, because as seen in Figures 2.C and D, the lacerations and hemorrhages presented a symmetrical curvature compatible to a medium size canine mouth, with the same size in different animals, as pointed out before. Moreover, the cyclicity of cases, led us to believe that these deaths could also be induced by a human guardian, since a possible aggressive errant dog would not choose a unique and same day of the week to hunt. Especially considering that the Campus remained closed during weekends, with the entrance of restricted to security personnel, suggesting their possible involvement because the time of death was about 8 to 12 hours before, that is on the same day early, or on the day before (Sunday). **Conclusion:** Necroscopic examination, along with complementary investigations, was determinant to produce important evidences that someone intentionally led a dog, for several times, to attack the feline population within the Campus, even knowing its massive consequences. Moreover, according to the current legislation in Brazil (Article 936 of the Civil Code – Law 10406/02), the owner is the person in charge to respond for any accidents caused by the animal, except in particular situations. Thus, it would be equally expected for the responsible to be “hunted” and correctly punished.,

References

ARMED FORCES INSTITUTE OF PATHOLOGY. **Technical Bulletin Med. nº 283:** veterinary necropsy protocol for military working dogs and pathology specimen submission guidelines. Washington, D.C.: Department of the Army, 2001.

BROOKS, J. W. Postmortem changes in animal carcasses and estimation of the postmortem interval. **Veterinary Pathology**, Thousand Oaks, v. 53, n. 5, p. 929-940, 2016.

CUEVAS, S. E. C. *et al.* Papel da patologia forense veterinária na investigação de óbito sob circunstâncias desconhecidas de um cão. **Revista de Educação Continuada em Medicina Veterinária e Zootecnia do CRMV-SP**, São Paulo, v. 14, n. 1, p. 49, 2016.

FRANÇA, G. V. **Medicina legal**. 10. ed. São Paulo: Guanabara Koogan, 2015.

PEIXOTO, P. V.; BARROS, C. S. L. A importância da necropsia em medicina veterinária. **Pesquisa Veterinária Brasileira**, Rio de Janeiro, v. 18, n. 3-4, p. 132-134, 1998.

TOUROO, R.; FITCH, A. Identification, collection, and preservation of veterinary forensic evidence: on scene and during the postmortem examination. **Veterinary Pathology**, Thousand Oaks, v. 53, n. 5, p. 880-887, 2016.

A DOG DEATH IN A HIT AND RUN ACCIDENT

MATOS, M. G.¹; VIANA, D. A.²; LOPES, C. E. B.¹; PIMENTEL, S. P.¹; RODRIGUES, F. R. N.¹

¹ Undergraduate student of Veterinary Medicine at Universidade Estadual do Ceará (Uece). E-mail: magna570@gmail.com.

² Professor of Animal Pathology, MSc, DSc (Uece) and Technical Scientific Director of Laboratório de Anatomia Patológica e Patologia Clínica S/S LTDA (Pathovet) (<http://www.pathovet.com.br>) – Fortaleza.

Introduction: The practice of veterinary forensic pathology is often precisely to give a voice to a voiceless animal victim of abuse or neglect and tell a well-documented story about an animal that has suffered or died (LOCKWOOD, 2016). In human legal medicine, a lot of hit and run cases are the reason for corpse evaluation. The investigation of hit-and-run road accidents is a special challenge to forensic medical examiners requiring a multiskilled approach (FRANÇA, 2015). In the medical literature, the principles of patient evaluation were demonstrated primarily on the basis of hit-and-run fatalities, but they also apply to clinical forensic medicine (DODD, 2000). In forensic necropsies, a multiskilled approach is also needed. It is fundamental to exam carefully all the external and internal bruises, fractures and other signs of trauma and try to link the shapes and severity of damage caused with a hypothesis about the source of the impact suffered by the body (BROWNLIE, 2016). The present paper is a case report of death caused by trauma in consequence of a hit and run, an animal related crime unfortunately not uncommon in veterinary forensic necropsy investigations. **Case Description:** An young male adult, Yorkshire Terrier dog, was analyzed and verified accord to forensic traumatology after the request of a necropsy exam by the witness who found it on the street. The necropsy